

**Original Paper, Oncology****Added Value of PET-CT in Patients with Metastases of Unknown Primary****Abougabal, M<sup>1</sup>. Taher, A<sup>2</sup>. Fathy H<sup>3</sup>. Gomaa, M<sup>4</sup>**

*<sup>1</sup>Department of Oncology & Nuclear Medicine, Faculty of Medicine. <sup>2</sup>Radiotherapy department. <sup>3</sup>Nuclear Medicine Unit and <sup>4</sup>Radiology department, National Cancer Institute, Cairo University. Egypt.*

**Purpose:** To assess the value of PET/CT in metastases of unknown primary. **Materials and methods:** prospective analysis of 100 patients, presenting with pathology proved or clinically suspected metastatic lesions of unknown primary, all patients had undergone prior investigations with clinical examination and routine workup with follow up for a period of 3-9 months. **Results:** PET/CT findings among 100 patients of study group: 64 patients were true positive, 4 patients were false

positive, 9 patients were true negative & 23 patients were false negative with sensitivity of 73.6% and specificity of 69.2%. PET-CT detected more additional sites of metastases in 64 patients.

**Conclusion:** FDG PET/CT is a single modality that has advantage for early detection of the primary tumor site in CUP patients. This facilitates early selection of appropriate treatment protocols that will improve patients' prognosis.

**Key words:** CUP, FDG PET/CT.

**Corresponding author:** Abougabal, M.

**E-mail:** *Kodomojanai20@yahoo.com*

## INTRODUCTION:

There is some inconsistency between the definition of CUP both in clinical practice and in literature. A histologically proven cancer with no primary despite completed staging; or patients with metastases without known primary site based on clinical findings only<sup>(1)</sup>. However, the simplest clinical definition has included all patients who presented with histologically confirmed metastatic carcinoma and in whom a complete medical history, careful physical examination, and chest radiography did not identify the primary site<sup>(2)</sup>

CUP is the seventh to eighth most frequently occurring cancer in the world and the fourth commonest cause of cancer-related death in both men and women<sup>(2)</sup>. The majority of CUP (60–65%) are adenocarcinoma, 5% are squamous cell carcinoma, while the remaining 30–35% are poorly differentiated adenocarcinoma or poorly differentiated carcinoma, poorly differentiated neoplasm. Investigations including blood biochemistry survey, stool occult blood testing, urine analysis, histopathologic review of biopsy material with the use of immunohistochemistry and computed tomography of head & neck, chest, abdomen & pelvis are usual investigations in such patients<sup>(3&4)</sup>.

Additional diagnostic procedures that can be used for primary tumor detection include a combination of various endoscopy and serum tumor marker studies, depending on the specific signs and symptoms, histological results, and laboratory abnormalities. However, in majority of patients these tests may eventually fail to detect a primary tumor.

PET/CT, using 18Ffluoro- 2-deoxyglucose (FDG) is whole body imaging that may help in problem-solving in patients with CUP. To identify patients with treatable CUP subsets, and accelerates the diagnostic work up<sup>(5&6)</sup>. Compared to conventional imaging technologies, PET provides information about functional or metabolic characteristics for detection of malignancies before changes occur in anatomical structure<sup>(7)</sup>. Since the vast majority of malignant cancer phenotypes exhibit an increased glucose metabolism so the radiotracer FDG is useful for detection of unknown primary tumor site<sup>(8)</sup>. In CUP the primary tumor may be of small size below the spatial resolution of a PET system unless intense FDG uptake is present<sup>(9)</sup>. The most frequently reported PET-CT detected unknown primary tumor locations include the lung, pancreas and oropharynx<sup>(5)</sup>. PET/CT is a useful adjunctive imaging modality when

conventional cross-sectional imaging is non-diagnostic, to differentiate pancreatic from chronic pancreatitis. Several studies have shown that PET/CT has high rates of sensitivity (85-100%) and specificity (67-99%) for distinguishing benign from malignant pancreatic masses <sup>(10&11)</sup>.

Using combined PET/CT demonstrated a higher sensitivity and specificity of 100% and 92.5%, respectively ( $P < .00005$ ) in diagnosing a malignant pelvic tumor of unknown origin and elevated risk of malignancy based on a substantially elevated serum CA125, ultrasound examinations, and menopausal state <sup>(12&13)</sup>.

PET/CT is the image modality of choice

## **PATIENTS & METHODS:**

**Patient Population:** A retrospective analysis of 100 patients (48 women and 52 men, median age: 55.1 years) presented with metastatic lesions of unknown primary where collected from three centers (children cancer hospital, national cancer institute and Naser hospital) during the period of October 2010 till May 2014, all patients were referred for whole-body 18F-FDG PET/CT for localization of the primary tumor site. All patients had undergone prior investigations with clinical examination, serum tumor markers, CT for chest & abdomen, upper & lower GIT

when ultrasound showed a pelvic tumor when additional information is needed prior to surgery was needed.

The most common cause of metastatic involvement of axillary lymph nodes in women is ipsilateral breast cancer<sup>(14)</sup>. A baseline FDG-PET/CT may also play a valuable role for treatment monitoring following therapeutic intervention <sup>(15)</sup>.

Therapy directed at the presumed primary site which lead to benefits in these patients, and this supports the idea that at least some CUPS retain similar sensitivity to therapies that are known to be useful for the known primaries <sup>(16)</sup>.

endoscopies on individual basis according to clinical and laboratory findings.

According to sites of metastases on presentation: 26 had skeletal metastases , 24 patients had lymph nodes, , 22 patients had liver metastases, 10 patients had malignant effusions, 8 had cerebral metastases, 5 patients had lung nodules, and 1 had chest wall metastases and the remaining 4 patients were presented with more than one site of metastases (*table 1*).

**PET/CT scanning:** Patients fasted for 4-6h before PET scanning to minimize blood insulin levels and glucose utilization of normal tissue with blood sugar level not

more than 160mg/dl. Each patient was injected with 0.14 mCi/kg of body weight with F-18 FDG. During the uptake phase of 18F-FDG patients were laid still in a quite warm room. Whole-body images were acquired 45-60 min after intravenous injection of FDG. At first low dose contrast CT was performed prior to PET. Five millimeter thick sections are obtained at 80 mA (but adjusted for body thickness) and 120 kVp from the skull base to the mid-thigh, sometimes from the high parietal region till the feet and in some patients late images were obtained. Subsequently 3D whole body PET scan with an acquisition time of 3 minutes per bed position for approximately six to seven bed positions is performed. CT transmission map was used for attenuation correction. For PET/CT fusion images were also reconstructed transverse, coronal and sagittal slices in two sets with and without attenuation correction.

**Image analysis:** Whole-body images were interpreted by 2 nuclear medicine physicians'. All images were qualitatively & quantitatively interpreted.

Qualitative assessment the criterion for malignancy was [18F] FDG hyper metabolism at the site of pathological changes on CT or marked focal hyper metabolism at sites suggestive of

malignancy despite absence of on CT findings. Quantitative evaluation using Standard Uptake Value (SUV) of more than 2.5 was considered significant.

Clinical, surgical and histopathologic findings and correlative imaging modalities were used to assess the results of FDG PET. **Management of patients:** 78 received irradiation with/without chemotherapy whether in a palliative setting or a radical one. Mainly a 2D technique was adopted for the palliative setting, in case of brain metastasis; dose of 30 Gy /10 fractions was administered. In case of bone metastasis dose ranged from 750 cGy single shot up to 500 cGy x 4 fractions or 300 cGy x 10 fractions. 3D conformal irradiation technique was used to deliver radical irradiation to head and neck region and prostate cancer with radiation dose of 70 Gy/ 35 fractions. **Follow up:** All the included patients were followed up for a period of 3-9 months after starting treatment with either radiotherapy & chemotherapy according to each site. **Statistical Analysis:** The accuracy of FDG-PET was expressed in terms of sensitivity, specificity, accuracy, positive & negative predictive values. The difference in accuracy was tested using the chi-square test.

## RESULTS:

The baseline characteristics of patients included in the study were summarized in *table 1*.

**Table 1: Characteristics of 100 patients with metastases of unknown primary**

Male/Female	52/48	
Median Age	55.1	
Site of lesions on presentation	Bone	26
	LN's	24
	Liver	22
	Malignant effusion	10
	Brain	8
	Lung	5
	Chest wall	1
	More than one site	4

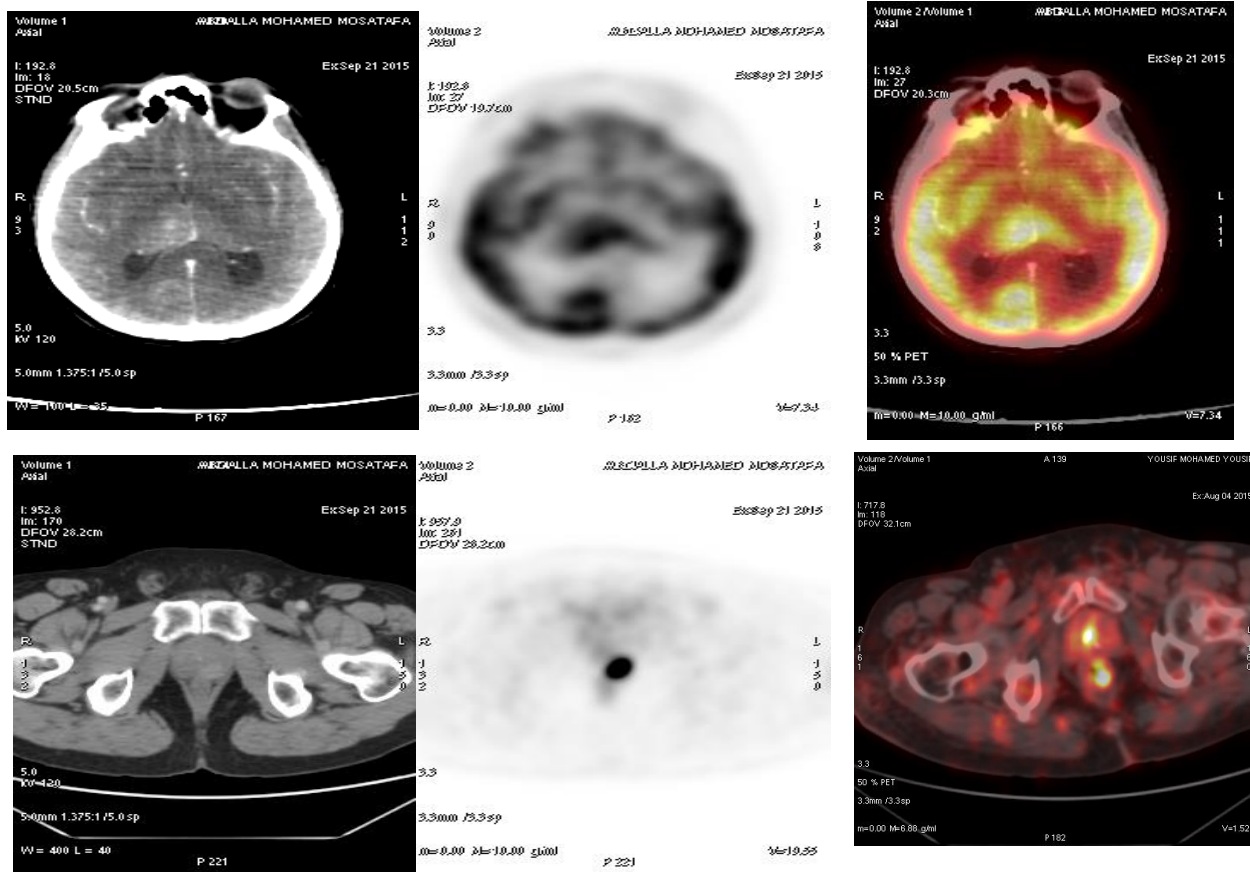
PET-positive lesions suggestive of primary malignant tumors were found in 68 out of 100 patients. These lesions were pathologically proven to be malignant (TP) in 64 patients (64%).

The proven sites of the malignant primary lesion are listed in table 2 with higher

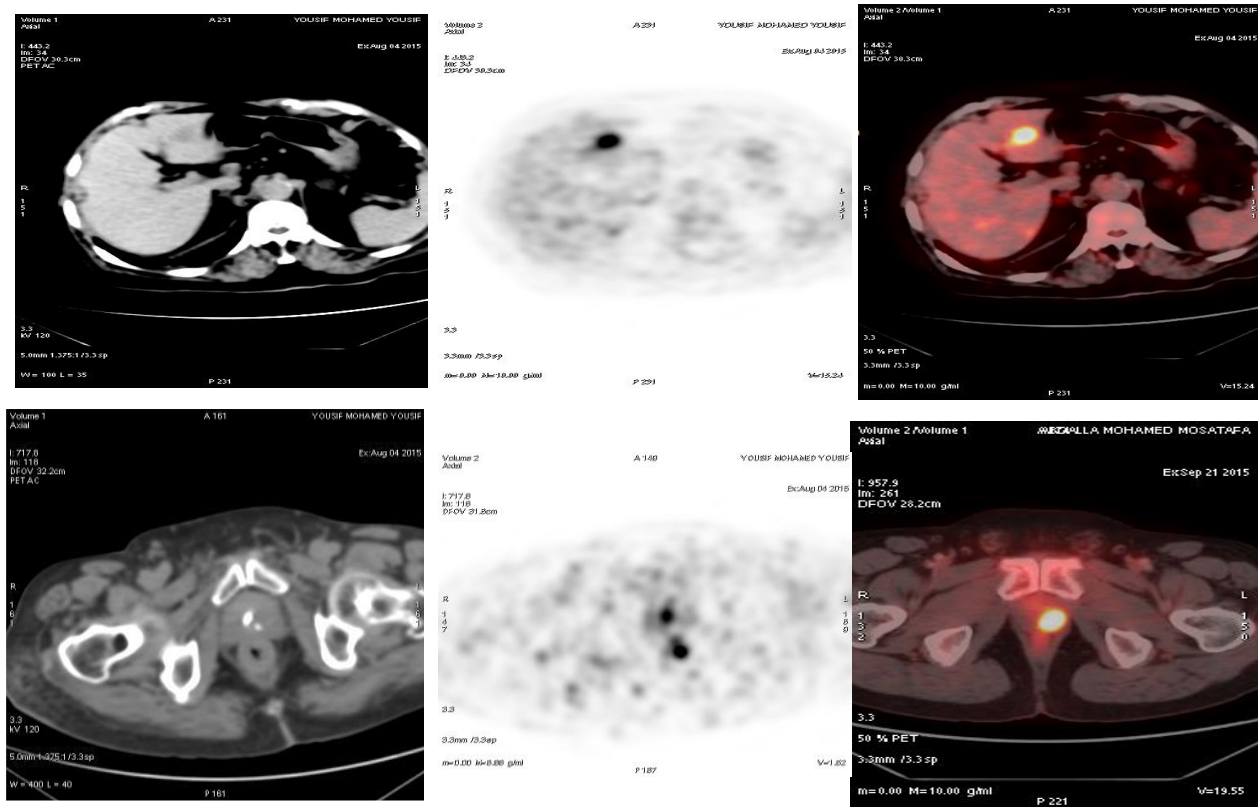
detection rate in lung, Pancreas, breast and colon as primary site. The remaining 4 patients showed false positive hyper metabolic FDG uptake in hyperplastic colonic polyp, pulmonary T.B, non-specific inflammatory lung lesion and sarcoidosis.

**Table 2:** Sites of pathologically proved primary tumor in 64 positive patients as detected by PET/CT.

Site of primary		N0 Of patients
	Lung	14
	Pancreas	9
	Breast	8
	Colon	7
	Ovarian mass	5
	Prostate	4
	Lymphoma	4
	Liver mass	3
	Renal	2
	Uterine	2
	Thyroid	2
	Others	5
	<b>Total</b>	<b>64</b>



**Figure 1:** 60 years old male patient presented with brain deposit. PET/CT showed prostatic lesion which proved histologically to be the primary site of origin.



**Figure 2:** a 43 years old male patient presented by liver metastasis, PET/CT showed focal uptake at the rectal wall proved to be rectal carcinoma by after surgical excision.

On the other hand, PET/CT could not detect primary lesion in 32 patients. However during the follow up period, primary site was detected and histologically confirmed in other 3 patients (1 patient had multiple myeloma, 1 patient had cancer breast & 1 patient had cancer of valleculla).

Among the remaining 29 patients during follow up period 9 patients proved to be true-negative (TN). One patient proved to be osteoporosis with multi-level porotic collapse after dorsal vertebral decompression, the second patient proved to be hyperparathyroidism with brown tumor, the third patient proved to be pancreatitis, the fourth patient proved to be meningioma after surgical intervention. Two patients proved to have regeneration nodules in liver, one patient after revision of the lymph node biopsy confirmed to be

hyperplasia. One patient confirmed to be stress fracture in the ribs with inflammatory soft tissue component and the 9th patient proved to be Paget's disease in bone. The remaining twenty patients showed no evidence of primary tumor site during follow up and considered as false negative (FN).

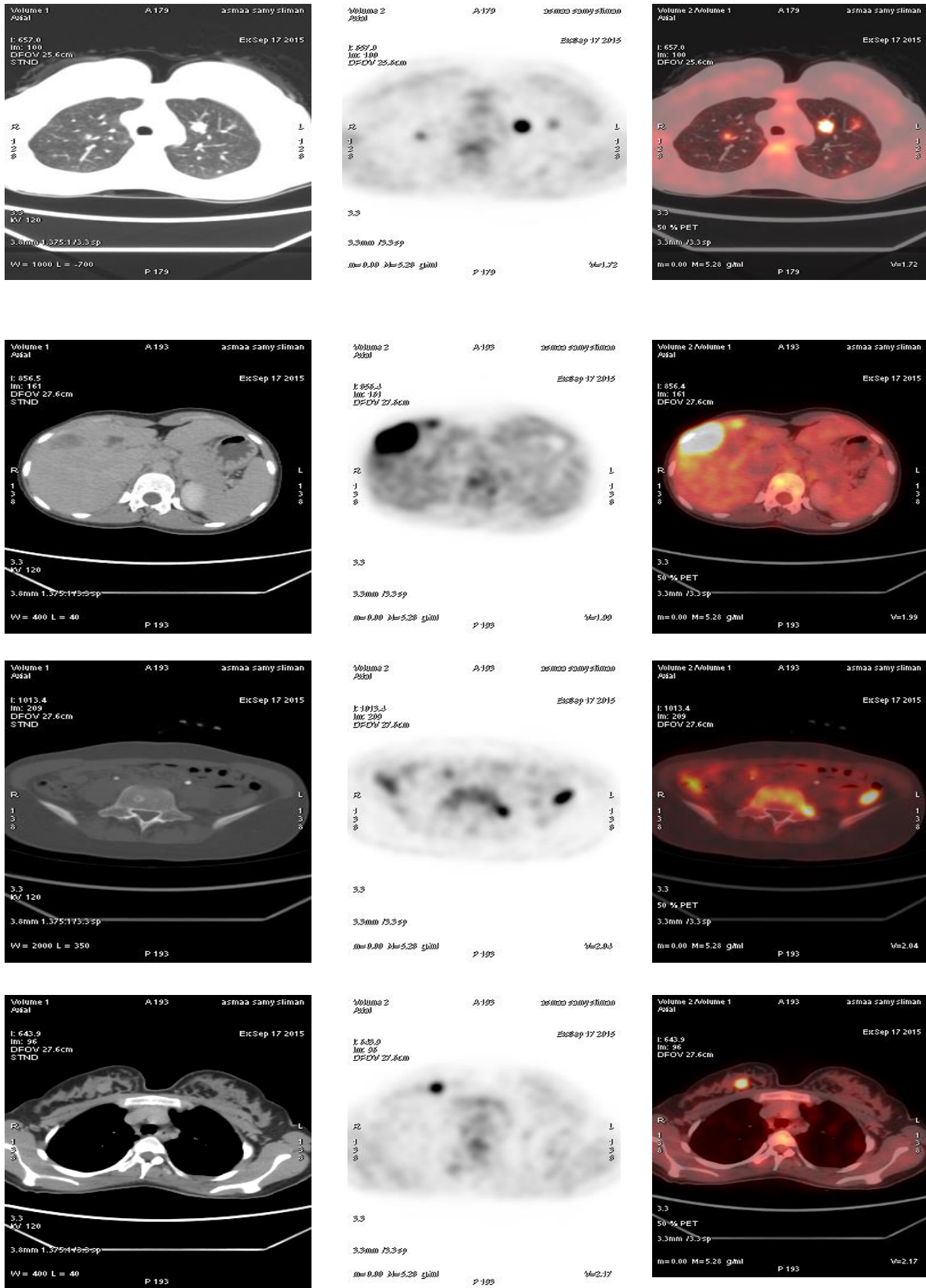
PET/CT findings among 100 patients of study group:

Thus the true total positive pathologically proved primary tumor site by PET/CT were 64 patients (64%), 4 false positive patients (4%), 9 true negative patients (9%) and 23 false negative patients (23%) with sensitivity, specificity, PPV, NPV and accuracy of FDG-PET in the search for the presence of a primary in cases of CUP are seen in table 3.

**Table 3:** sensitivity, specificity, PPV and NPV of FDG-PET among the 100 patients with CUP.

Sensitivity	Specificity	PPV	NPV	Accuracy
73.6%	69.2%	94.1%	28.1%	73%

PET-CT detected other sites of metastases in 64 patients in form of 106 added lesions distributed as in table 4. the highest lesions detected were in lymph nodes ( 50 sites) then skeletal metastases (29 sites) followed by the lungs ( 15 sites) .



**Figure 4:** A 36years old female patient presented with lung deposits, PET/CT study revealed additional deposits in liver, bone and nodes; also the suggested primary is breast that is histologically proved later on.



**Table 4:** Distribution of the added metastatic lesions according to the site among 64 patients.

Site of additional lesions	Number of lesions
Lymphatic metastases	50
Skeletal metastases	29
Lung metastases	15
Liver metastases	6
Adrenal metastases	4
Brain metastases	2

## DISCUSSIONS:

Postmortem examinations reveal a putative primary site in 60%–80% of CUP patients, most often in the lung (27%), pancreas (24%), and hepatobiliary tree (8%). Failure to identify the primary tumor site may negatively influence patient management as tailored chemotherapeutic regimens and targeted agents have been increasingly developed over the last decade for a number of solid tumors<sup>(17, 18)</sup>.

In the present study, FDG-PET was able to identify the primary site in 64 out of 100 patients (64%) presenting with either pathologically proved or clinically suspected malignancy. These results were pathologically confirmed (true positive). PET suggested primary sites in 4 patients which confirmed during follow up to as benign lesions (False Positives). In the remaining 32 patients FDG-PET did not

identify a primary tumor site with 9 proved to be true negative. 3 patients eventually became clinically evident malignant during follow up (FN). In the remaining 20 patients, the primary site was not detected. However, they underwent empirical chemotherapy but they were considered as false negative patients. So, PET/ CT had a sensitivity of 73.6% & specificity of 69.2%, in detection of unknown primary in the present study.

*Seve et al., 2007*<sup>(19)</sup> they reported a detection rate for primary tumor around 63% with overall sensitivity & specificity of 91.9% & 81.9% respectively. Similarly, *Fleming et al., 2007*<sup>(20)</sup> reported detection rate for primary tumor of 73% with sensitivity of 94% and higher specificity of 100% as their study included patients with cervical metastases only.

Also, **Pavel et al., 2007**<sup>(21)</sup> in the search for the site of a primary reported lower sensitivity of 62.0% with a specificity of 81.9%. **Moustafa et al., 2009**<sup>(22)</sup> in a retrospective study including 29 patients with CUP, FDG PET was able to detect primary tumor in 25 patients of them (64.1%) with lungs the common detect primary tumor site representing 12 out of 25 detected primary site. **Moller et al., 2011**<sup>(23)</sup> reported that PET/CT detected the primary tumor in 39.5% of patients with extra-cervical CUP with sensitivity, specificity, and accuracy of 87%, 88% and 87.5% respectively. **Tamam et al., 2012**<sup>(24)</sup> reported similar results with sensitivity of 81% and the specificity 45%. Positive predictive value, negative predictive value and diagnostic accuracy were 95%, 15% and 78%, respectively.

On the other hand, **Bruna et al., 2007**<sup>(25)</sup> reported a lower detection rate of primary tumor of 38% with comparable sensitivity & specificity of 93% & 77 % respectively.

**In the present study**, False Positive results were evidently in 4 patients including tuberculosis, sarcoidosis, hyperplastic colonic polyp & inflammatory lung lesion. Similar **Metser & Even 2007**<sup>(26)</sup> as well as **Dong et al., 2008**<sup>(27)</sup> found that inflammatory lesions were among the most common non oncological causes of FDG uptake with 37% of benign lesions being inflammatory in nature. So a careful review

of the patient's history and clinical examination is of utmost importance to increase specificity of FDG-PET/CT. In addition, the CT imaging pattern may suggest the presence of benign inflammatory disease. In a study by **HU et al., 2011**<sup>(28)</sup> PET/CT showed 13 false positive results, 12 patients either had specific infections (tuberculosis, granuloma), non-specific infections, or benign tumors.

To reduce the number of false positive results, the applicability of dual-time-point FDG PET/CT imaging may help to differentiate between benign and malignant nodules<sup>(29)</sup>.

**In our study**, 3 patients were proved to be falsely negative by PET/CT involving: cancer breast, cancer vallecula & multiple myeloma. **Chen et al., 2005**<sup>(30)</sup> reported that false negative results in small tumor sizes below the resolution of FDG-PET or low-grade tumors that tend to have low FDG uptake.

An important aspect of FDG PET/CT that should be considered is its ability to identify or rule out additional metastatic sites, which may have important implications in patient management. Also, detection of additional lymph node involvement based upon the FDG PET/CT study might help in modifying and planning the radiotherapy field appropriately, which is the pivotal modality of therapy in these

patients. Furthermore, a baseline FDG PET/CT may also play a valuable role for treatment monitoring following therapeutic intervention <sup>(15)</sup>.

**HU et al., 2011** <sup>(28)</sup>, FDG PET/CT detected primary tumors in 24.8% of patients that were not apparent after conventional workup. Also, FDG PET/CT uptake in forty-seven out of 149 (31.5%) patients

underwent a change in therapeutic management.

**In our study**, in addition to the ability of PET/CT in detection of primary tumors in 64% of patients, additional sites of metastases were evident in 64 of 100 patients which lead to change patient management in these patients, with 53% of them received specific therapy and 11% underwent surgery with curative intent.

## CONCLUSIONS:

FDG-PET detected the primary tumor in 64% of CUP patients with the lung being the common primary tumor site in our study. FDG-PET/CT improves the accuracy of diagnosis in patients with CUP

syndrome with sensitivity of 73.6% and specificity of 69.2%. which may help in selection of appropriate treatment protocols that will improve patients' prognosis.

## REFERENCES:

1. **Alwin Karmar and Harald Loffler.** cancer of unknown primary. chapter1, page2; 2015.
2. **Pavlidis N, Fizazi K.** Carcinoma of unknown primary (CUP). Crit Rev Oncol Hematol. 69:271–8; 2009.
3. **Haas I, Hoffmann TK, Engers R, Ganzer U.** Diagnostic strategies in cervical carcinoma of an unknown primary (CUP). Eur Arch Oto-rhinolaryngol. 259:325–3; 2002.
4. **Varadhachary Gauri R. & Abbruzzese James L.** Carcinoma of unknown primary. Harrison's principles of internal medicine 18th edition. 99: 821-825; 2012.
5. **Kwee TC, Basu S, Cheng G, Alavi A:** FDG PET/CT in carcinoma of unknown primary. Eur J Nucl Med Mol Imaging. 37:635-644; 2010.
6. **Kazmierczak PM, Nikolaou K, Rominger A, Graser A, Reiser MF, Cyran CC.** Radiological diagnostics in CUP syndrome. Radiologe. 54(2):117-23; 2014.
7. **Kitagawa Y, Nishizawa S, Sano K, Ogasawara T, Nakamura M, Sadato N, Yoshida M and Yonekura Y.** Prospective comparison of 18F-FDG PET with conventional imaging modalities (MRI, CT, and 67Ga scintigraphy) in assessment of combined intra-arterial chemotherapy and radiotherapy for head and neck

- carcinoma. *J Nucl Med.* 44: 198-206; 2003.
8. **Rohren, E.M., Turkington, T.G., Coleman, R.E.** Clinical applications of PET in oncology *Radiology.* 231,305–32; 2004.
  9. **Kapoor V, McCook BM, Torok FS.** An introduction to PET-CT imaging. *Radiographics.* 24:523–43; 2004 .
  10. **Heinrich S, Goerres GW, Schafer M, SagmeisterM, Bauerfeind P, Pestalozzi BC, et al.** Positron emission tomography/Computed tomography influences on the management of respectable pancreatic cancer and its cost-effectiveness. *Ann Surg.* 242:235-43; 2005.
  11. **Delbeke D, Martin WH.** PET and PET/CT for pancreatic malignancies. *Surg Oncol Clin N Am.*19:235-54; 2010.
  12. **National Cancer Information Center.** Goyang: National Cancer Information Center. c [cited 2011 Dec 20]. Available from: [http://www.cancer.go.kr/ncic/cics\\_f/02/02\\_2/index.html](http://www.cancer.go.kr/ncic/cics_f/02/02_2/index.html); 2011.
  13. **Risum S, Hogdall C, Loft A, et al.** The diagnostic value of PET/CT for primary ovarian cancer-a prospective study. *Gynecol Oncol.*105: 145–149; 2007.
  14. **Banzo J, Ubieta MA, González C, Razola P, Tardín L, Andrés A, Santapau A, Parra A, Rambalde EF, Prats E.** Papillary Thyroid Carcinoma synchronous with breast cancer: an incidental finding in an <sup>18</sup>F-FDG PET-CT study carried out in a search for occult breast cancer. *Rev Esp Med NuclI magen Mol.* 2012 Jul-Aug; 31 (4): 213-5. doi: 10.1016/ j.remn. 2011.11.009. Epub May 30; 2012.
  15. **Basu, S., Alavi, A.** FDG-PET in the clinical management of carcinoma of **unknown** primary with metastatic cervical lymphadenopathy: shifting gears from detecting the primary to planning therapeutic strategies *Eur J Nucl Med Mol Imaging.*34, 427–8; 2007.
  16. **Greco FA, Hainsworth JD.** Introduction: unknown primary cancer. *SeminOncol.*36:6–7; 2009.
  17. **Pentheroudakis G, Greco FA, Pavlidis N.** Molecular assignment of tissue of origin in cancer of unknown primary may not predict response to therapy or outcome: A systematic literature review. *Cancer Treat Rev.* 35:221–227; 2009.
  18. **Kwee, T.C., Kwee, R.M.** Combined FDG-PET/CT for the detection of unknown primary tumors: systematic review and meta-analysis *EurRadiol.*19, 731–44; 2010.
  19. **Sève P, Billotey C, Broussolle C, Dumontet C, Mackey JR.** The role of 2-deoxy-2-[F-18] fluoro-D-glucose positron emission tomography in disseminated carcinoma of unknown primary site. *Cancer.* Jan 15; 109(2):292-9;2007.
  20. **Fleming AJ, Smith SP, Paul CM et al.** Impact of [18F]-2-fluorodeoxyglucose-positron emission tomography/ computed tomography on previously untreated head and neck cancer patients. *Laryngoscope.*117:1173–1179; 2007.
  21. **Pavel Fencl, Otakar Belohlavek, Magdalena Skopalova, Monika Jaruskova, Iva Kantorova & Katerina Simonova.** Prognostic and diagnostic

- accuracy of [18F] FDG-PET/CT in 190 patients with carcinoma of unknown primary. *Eur J Nucl Med Mol Imaging*. 34:1783–1792; 2007.
22. **Moustafa HM, Taalab KM, A. El Hamid HF, Ahmed EA.** Role of PET in detecting primary site in patients with metastatic cancer of unknown primary. *Egyptian Journal of nuclear medicine*; 2009.
23. **Moller AK, Loft A, Berthelsen AK, Damgaard Pedersen K, Graff J, Christensen CB, Perell K, Petersen BL, Daugaard G.** 18F-FDG PET/CT as a diagnostic tool in patients with extracervical carcinoma of unknown primary site: a literature review. *Oncologist*. 16 (4): 445-51; 2011.
24. **Tamam MO, Mulazimoglu M, Guveli TK, Tamam C, Eker O, Ozpacaci T.** Prediction of survival and evaluation of diagnostic accuracy whole body 18F-fluoro-2-deoxyglucose positron emission tomography/ computed tomography in the detection carcinoma of unknown primary origin. *Eur Rev Med Pharmacol Sci*. Dec; 16(15):2120-30; 2012.
25. **Bruna C, Journo A, Netter F et al.** On the interest of PET with 18FFDG in the management of cancer of unknown primary (CUP). *Med Nucl*. 31:242–249; 2007.
26. **Metser, U., Even-Sapir, E.** Increased (18)F-fluorodeoxyglucose uptake in benign, non physiologic lesions found on whole-body positron emission tomography/ computed tomography (PET/CT): accumulated data from four years of experience with PET/ CT. *Semin Nucl Med* 37, 206–22; 2007 .
27. **Dong MJ, Zhao K, Lin XT, Zhao J, Ruan LX, Liu ZF.** Role of Fluoro-deoxyglucose PET versus fluorodeoxyglucose-PET/ computed tomography in detection of unknown primary tumor: a meta-analysis of the literature. *Nucl Med Commun*. Sep; 29 (9): 791-802; 2008.
28. **HU Man, ZHAO Wei, ZHANG Pin-liang, JU Gui-fang, FU Zheng, ZHANG Guo-li, KONG Li, YANG Yan-qin, MA Yi-dong and YU Jin-ming.** Clinical applications of 18F-fluorodeoxyglucose positron emission tomography/computed tomography in carcinoma of unknown primary. *Chin Med J*; 124(7):1010-1014; 2011.
29. **Israel O, Yefremov N, Bar-Shalom R, et al.** PET/CT detection of unexpected gastrointestinal foci of 18F-FDG uptake: incidence, localization patterns, and clinical significance. *J Nucl Med*. 46:758–762; 2005.
30. **Chen YK, Ding HJ, Chen KT, Chen YL, Liao AC, Shen YY, et al.** Prevalence and risk of cancer of focal thyroid incidentiloma identified by 18-f fluorodeoxy glucose positron emission tomography for cancer screening in healthy subjects. *Anticancer Res*. 25:1421-1426; 2005.